

# PenRad

10580 Wayzata Blvd., Suite 200, Minnetonka, MN 55305  
Phone: 763.475.3388 Fax: 763.475.2815 www.penrad.com

## PenVoice

### Voice command and audio playback system

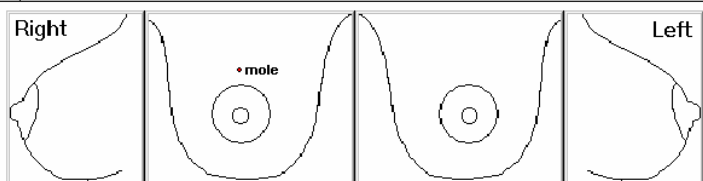
PenVoice is another innovative productivity tool for mammography. PenVoice extends PenRad's tap-on tap-off, and auto negative technology, by incorporating voice commands.

Compared to other voice recognition products, PenVoice is 100% focused on PenRad's keywords for accurate report generation, and does not require any manual editing.

PenVoice incorporates audio feedback of key exam information, then responds to spoken keywords to generate the narrative report, providing a hands free, heads up solution.

As soon as the exam is selected, PenVoice speaks the pertinent exam information, allowing the radiologist to listen while studying the images, eliminating the need to review screens, film jackets, and /or other paperwork. As the radiologist is interpreting the images, he/she speaks a few PenRad keywords and the report is generated. For additional assurance, spoken keywords are repeated back as a confirmation.

For example: As the exam is opened, PenVoice recites the patient's name, date of birth, age, medical record number, exam type, risk factors and indicated problems.

Pre-Exam		Christine Jade Anderson, Penrad Main Clinic	4/1/2006 07:30:28
Dorothy Y. Yon DOB: 11/11/1934 AGE: 71 F PID: 223238204 SSN: 223238204 CHT: ACCT:			
			
Comparison Films		Indicated Breast Problems	
11/02/2002 Bilateral, screening mammogram film 02/02/1997 Bilateral, screening mammogram film		03/31/2005 Mammography: brads 1 - 1 year screening 11/02/2002 Mammography: brads 1 - 1 year screening 02/02/1997 Mammography: brads 0 - 1 year screening	
Medical History		Previous Procedures	
1st menstruation, 1948, age 14		2005, age 70, Mammogram (normal), B: Bi 2002, age 67, Mammogram (normal), B 1997, age 62, Mammogram needed addl.	
		Risk Factors	
		(Post-menopausal) No family history (of breast cancer)	
		Negative Mammo Detailed Mammo Track Only Mammo	
		Procedures	
		Notes Imaging Edit Patient Print Hist Exit Help	

Approve Normal Mammogram Exam		Christine Jade Anderson, Penrad	4/1/2006 07:37:02
Dorothy Y. Yon DOB: 11/11/1934 AGE: 71 F PID: 223238204 SSN: 223238204 CHT: ACCT:			
Change Rad. Dr. Christine Jade Anderson M.D., Penrad Main Clinic		Exam Date / Time: 03/09/2006 14:22 ?	
Clear Change 2nd Rad.		BI-RADS 1 - Negative	
Clear Change Attend Tech.		<input type="checkbox"/> Manual Override	
Clear Change Imaging Tech. Sue T Anderson, Penrad Main Clinic		Patient Letter No Letter	
Exam Type Screening mammogram, bilateral		1. Mammography Norm	
Tissue Density Predominantly Fatty		2. Comparison to Prev	
Changes NO significant changes			
# Films Used		Recall Interval	
Compared to 11/2/2002, 2/2/1997		No Recall (discretionary)	
Additional BENIGN Breast Composition		No Recall- no msg	
Right Breast Left Breast		6 month screening	
Cyst Cysts		1 year screening	
Mass Masses		2 year screening	
Density Densities		3 year screening	
Calcification Calcifications		4 year screening	
Lymph node Lymph nodes		5 year screening	
Scattered densities		12 month follow-up	
Scattered calcifications		Add Mammo Text Summary Text	
Vascular calcifications		Preview Coding	
Post-op findings		Dictate / Modify	
Appears benign		Detailed Mammo	
		Approve	
		Approve For 2nd Read	
		Approve and Print Now	
		To Preexam Help	

If the radiologist speaks 'Negative', PenVoice responds with 'Fatty, No Change, One Year, Letter One' reflecting predominately fatty breast tissue, no changes from the comparison images, return in one year and send the patient the normal exam letter.

Saying 'Approve' completes the report and returns the radiologist to the Scheduled Patients list to select the next exam.

If the radiologist chooses to say 'Bilateral Calcs', PenVoice will respond with 'Bilateral Calcifications' and modify the report convert BiRads to 2-Benign.

If the radiologist states 'Bilateral Calcs' a second time, PenVoice responds 'De-selecting Bilateral Calcifications' and reverts the report back to a BiRads 1-Negative.

Saying 'Approve' completes the report and returns the radiologist to the Scheduled Patients list to select the next exam.

Approve Normal Mammogram Exam		Christine Jade Anderson, Penrad		4/1/2006 07:40:57																																													
Dorothy Y. Von DOB: 11/11/1934 AGE: 71 F PID: 223238204 SSN: 223238204 CHT: ACCT:																																																	
<div>Change</div> <div>Clear Change</div> <div>Clear Change</div> <div>Clear Change</div>		Rad: Dr. Christine Jade Anderson M.D., Penrad Main Clinic 2nd Rad: Attend Tech: Imaging Tech: Sue T. Anderson, Penrad Main Clinic		Exam Date / Time: 03/09/2006 14:22 ? BI-RADS: 2 - Benign <input type="checkbox"/> Manual Override																																													
Exam Type: Screening mammogram, bilateral Tissue Density: <div> <div>Predominantly Fatty</div> <div>Scattered Fibroglandular</div> <div>Heterogeneously Dense</div> <div>Extremely Dense</div> </div> # Films Used:		Changes: NO significant changes Compared to: 11/2/2002, 2/2/1997 Additional BENIGN Breast Composition: <table border="1"> <thead> <tr> <th colspan="2">Right Breast</th> <th colspan="2">Left Breast</th> </tr> </thead> <tbody> <tr> <td>Cyst</td> <td>Cysts</td> <td>Cyst</td> <td>Cysts</td> </tr> <tr> <td>Mass</td> <td>Masses</td> <td>Mass</td> <td>Masses</td> </tr> <tr> <td>Density</td> <td>Densities</td> <td>Density</td> <td>Densities</td> </tr> <tr> <td>Calcification</td> <td>Calcifications</td> <td>Calcification</td> <td>Calcifications</td> </tr> <tr> <td>Lymph node</td> <td>Lymph nodes</td> <td>Lymph node</td> <td>Lymph nodes</td> </tr> <tr> <td>Scattered densities</td> <td></td> <td>Scattered densities</td> <td></td> </tr> <tr> <td>Scattered calcifications</td> <td></td> <td>Scattered calcifications</td> <td></td> </tr> <tr> <td>Vascular calcifications</td> <td></td> <td>Vascular calcifications</td> <td></td> </tr> <tr> <td>Post-op findings</td> <td></td> <td>Post-op findings</td> <td></td> </tr> <tr> <td>Appears benign</td> <td></td> <td>Appears benign</td> <td></td> </tr> </tbody> </table>		Right Breast		Left Breast		Cyst	Cysts	Cyst	Cysts	Mass	Masses	Mass	Masses	Density	Densities	Density	Densities	Calcification	Calcifications	Calcification	Calcifications	Lymph node	Lymph nodes	Lymph node	Lymph nodes	Scattered densities		Scattered densities		Scattered calcifications		Scattered calcifications		Vascular calcifications		Vascular calcifications		Post-op findings		Post-op findings		Appears benign		Appears benign		Recall Interval: <div> <div>No Recall (discretionary)</div> <div>No Recall- no msg</div> <div>6 month screening</div> <div>1 year screening</div> <div>2 year screening</div> <div>3 year screening</div> <div>4 year screening</div> <div>5 year screening</div> <div>12 month follow-up</div> </div> Patient Letter: <div> <div>No Letter</div> <div>1. Mammography Nor</div> <div>2. Comparison to Prev</div> </div>	
Right Breast		Left Breast																																															
Cyst	Cysts	Cyst	Cysts																																														
Mass	Masses	Mass	Masses																																														
Density	Densities	Density	Densities																																														
Calcification	Calcifications	Calcification	Calcifications																																														
Lymph node	Lymph nodes	Lymph node	Lymph nodes																																														
Scattered densities		Scattered densities																																															
Scattered calcifications		Scattered calcifications																																															
Vascular calcifications		Vascular calcifications																																															
Post-op findings		Post-op findings																																															
Appears benign		Appears benign																																															
		<div>Add Mammo Text</div> <div>Summary Text</div> <div>Preview</div> <div>Coding</div> <div>Dictate / Modify</div> <div>Detailed Mammo</div>																																															
		<div>Approve</div> <div>Approve and Print Now</div>		<div>Approve For 2nd Read</div> <div>To Preexam</div> <div>Help</div>																																													

## Requirements:

PenRad PenVoice software.  
 Computer with a standard sound card.  
 Microphone headset (USB recommended).  
 Windows XP or Windows 2000 Pro operating system.  
 Uses the Microsoft speech engine, no voice recognition software to purchase.



Copyright PenRad Technologies, Inc. 1997-2006 Patent Pending 04/01/2006 PN# S9500

FOR MORE INFORMATION CONTACT:

# PenRad

10580 Wayzata Blvd., Suite 200  
 Minnetonka, MN 55305  
 Telephone: 763.475.3388  
 Fax: 763.475.2815  
 Web: www.penrad.com

...the mammography information specialists...